

Enteral tube placement in newborns according to the modified measurement technique

Posicionamento de sonda enteral em neonatos segundo técnica modificada de mensuração

Rafaela Reiche André¹

Carolina Queiroz de Souza Mendes¹

Ariane Ferreira Machado Avelar¹

Maria Magda Ferreira Gomes Balieiro¹

Keywords

Infant, newborn; Probe; Enteral nutrition; Neonatal nursing

Descritores

Recém-nascido; Sonda; Nutrição enteral; Enfermagem neonatal

Submitted

August 29, 2017

Accepted

November 27, 2017

Abstract

Objective: To evaluate the effectiveness of the enteral tube measurement using the modified nose - ear - xiphoid (NEX) technique by disregarding the tube distal orifices for placement in newborns' neonatal gastric cavity.

Methods: A prospective study conducted in a neonatal unit of a teaching hospital in the city of São Paulo, based on the radiographic analysis of 60 radiographs of 28 newborns using enteral tubes measured by the modified technique, and who had thoracoabdominal radiography.

Results: The correct placement index according to analysis by position was 68.3% and 71.7%, according to evaluators 1 and 2, respectively. In the analysis by vertebrae, 95% of tubes were properly placed in the gastric cavity. There was a statistically significant association between height and location of the enteral tube according to evaluator 2.

Conclusion: The evaluated measurement technique presents a risk for inadequate enteral tube placement in newborns, and its application in clinical practice should not be encouraged.

Resumo

Objetivo: Avaliar a efetividade da mensuração de sonda enteral pela técnica modificada, nariz - orelha - apêndice xifoide, com desconto dos orifícios distais da sonda, para posicionamento na câmara gástrica de neonatos.

Métodos: Estudo prospectivo, desenvolvido em unidade neonatal de um hospital de ensino do município de São Paulo, a partir da análise radiográfica de 60 radiografias de 28 neonatos em uso de sonda enteral mensurada pela técnica modificada, submetidos à radiografia toracoabdominal.

Resultados: O índice de posicionamento correto, de acordo com a análise por posições, foi de 68,3% e 71,7%, segundo os avaliadores 1 e 2, respectivamente, enquanto na análise por vértebras, 95% das sondas estavam adequadamente localizadas na câmara gástrica. Ocorreu associação estatisticamente significante entre estatura e localização da sonda enteral, segundo o avaliador 2.

Conclusão: A técnica de mensuração avaliada apresenta risco para posicionamento inadequado da sonda enteral utilizada em neonatos, devendo ser desencorajada sua aplicação na prática clínica.

Corresponding author

Maria Magda Ferreira Gomes Balieiro
Rua Napoleão de Barros, 754,
04024-002, São Paulo, SP, Brazil.
mmfgbalieiro@unifesp.br

DOI

<http://dx.doi.org/10.1590/1982-0194201700083>



¹Escola Paulista de Enfermagem, Universidade Federal de São Paulo, São Paulo, SP, Brazil.

Conflicts of interest: Avelar AFM and Balieiro MMFG are associate editors of Acta Paulista de Enfermagem and did not participate in the evaluation process of the manuscript.

Introduction

The increased survival of preterm newborns has resulted in new clinical issues including nutritional needs. The introduction of early enteral nutrition plays a role in preventing comorbidities and ensuring adequate growth and development during the neonatal period.⁽¹⁾

The use of enteral tubes is one of the most common nursing procedures in the Neonatal Intensive Care Unit (NICU) and usually indicated for gastric decompression, enteral nutrition and medication administration.^(2,3) In the neonatal population, enteral tube placement techniques are not well standardized and errors in correct positioning often occur.⁽⁴⁾

In care practice, enteral tube placement techniques use several measurements to estimate the length of the tube to be introduced into the newborn (NB), namely the measurement from the tip of the nose to the ear lobe and until the xiphoid (NEX); from the tip of the nose to the ear lobe and from this point to the midline between the xiphoid and the umbilicus (NEMU); and from the tip of the nose to the ear lobe and from this to the umbilicus (NEU).^(4,5) There are also measurements based on formulas that consider weight or height classified by the child's age.⁽³⁾

In a review of cases of inadvertent insertion of nasogastric tubes into the respiratory tract of children, the presence of serious injuries and even death was evident. For this reason, authors affirm it is essential to verify the placement of all inserted tubes without the aid of direct visualization methods prior to feeding or medication administration.⁽⁶⁾

In the aforementioned measurement methods, placement errors occur^(4,5) thus, tests to confirm the precise localization of the tube are extremely important given the need of its use for feeding preterm infants. This procedure is of nurses' responsibility and frequently repeated during hospitalization.⁽⁵⁾

Among the methods for verification of tube placement found in the literature, the following stand out: ultrasound; measurement of gastric hydrogen ion concentration (pH) by aspiration, bil-

irubin, pepsin and trypsin; assessment of gastric aspirate characteristics; observation of blistering by placing the proximal end of the probe immersed in water; measuring the level of carbon dioxide at the proximal end of the probe; auscultation of bubbling sound in the epigastrium or upper left quadrant of the abdomen as air is introduced; and thoracoabdominal radiography.⁽⁷⁾

The thoracoabdominal radiography is considered gold standard for the verification of tube placement. However, in neonatology, newborns cannot be exposed to multiple radiographs for this purpose, since they already do this exam to perform other diagnoses.⁽⁸⁾ Thus, to reduce newborns' exposure to radiation, other methods for tube placement and verification should be considered, such as real-time visualization.⁽⁷⁾

Several techniques are used to measure the enteral tube without real-time direct visualization, but none of them is error free.⁽⁴⁾

In the neonatal unit of a teaching hospital in the city of São Paulo - Brazil, place of the practice of multidisciplinary residency in neonatology, the gastric enteral tube technique has some specificities such as: enteral tubes are in polyvinyl with minimal distance between distal and proximal orifices. Thus, by adopting this type of tube, the risk of error placement would be smaller when no orifices were before the gastroesophageal junction.

- The measurement technique used in the neonatal unit corresponds to the modified NEX, in which the distal orifices are disregarded in the measurement in order to ensure the orifices in the distal tip of the tube are correctly positioned in the gastric cavity. The technique adopted in this service is not described in the literature hence without scientific evidence to support its adoption.
- The measurement technique used in the neonatal unit corresponds to the modified NOAX, which consists of discounting the distal holes of the probe to start the measurement, with the justification of ensuring that the holes in the distal tip of the probe are correctly positioned in the gastric chamber.

The technique adopted in this service is not described in the literature, therefore without scientific evidence to support the adoption of such procedure.

From this experience emerged as a matter of study: Does the measurement of the gastric localization enteral catheter, discounting the distal orifices of the catheter, starting from the apex of the nose to the earlobe and from this to the xiphoid appendix ensures correct gastric positioning?

The inadequate placement of the gastric enteral tube can cause complications for newborns and influence their recovery. Confirmation of the tube placement before the cardiac valve can lead to perforation, aspiration of food, gastroesophageal reflux, and pneumonia. However, when it is placed near the pyloric junction and in the duodenum, it can cause malabsorption, diarrhea and inadequate weight gain.⁽⁸⁾

Different techniques of measurement of the tube are identified in different neonatal services and in the literature, and there is no consensus on the best method for the correct placement in the gastric cavity.^(3,9)

The aim of this study was to evaluate the effectiveness of the measurement of enteral tube using the nose - ear - xiphoid (NEX) technique by disregarding the distal orifices of the tube, for placement in the gastric cavity of newborns.

Methods

This is a prospective and descriptive study, performed in a neonatal unit of a teaching hospital in the city of São Paulo, Brazil.

It was a convenience sample consisting of 60 thoracoabdominal radiographs of 28 newborns using gastric enteral tube.

Inclusion criteria: radiographs of newborns, regardless of gestational age, who required enteral gastric tube and underwent thoracoabdominal radiography during hospitalization.

Exclusion criteria: radiographs of newborns with gastrointestinal malformations.

The studied variables were related to the characterization of the sample, therapy used in the newborn, the enteral tube and evaluation of the tube placement.

The variables related to the characterization of the sample were birth weight, weight at the day of data collection, height, sex, gestational age (GA), corrected gestational age (CGA), days of life, score Apgar in the first and fifth minutes of life, and main medical diagnosis.

Regarding the variables related to the therapy, were selected medication and respiratory support. The variables related to the gastric enteral tube characteristics were divided between tube characteristics: indication, caliber, insertion route, number of orifices and distance between orifices; and dietary characteristics: type of diet and form of administration. The variables related to the analysis of the tube placement were performed by two evaluators: analysis by position and analysis by vertebrae with the description of the centimeters deviated to the left.

All enteral tubes used in the study were made of polyvinyl. For the measurement of the tubes analyzed in the radiographs, was used the modified NEX technique, in which the measurement disregards the tube orifices and starts at the tip of the nose to the ear lobe and from the ear lobe to the xiphoid appendix.

The determination of the tube placement was performed by radiographic analysis by two trained nurses. The nurses' training was performed by specialists in radiology before the beginning of the study, and included the joint analysis, discussion and confirmation of the findings of serial neonatal abdominal radiographs.

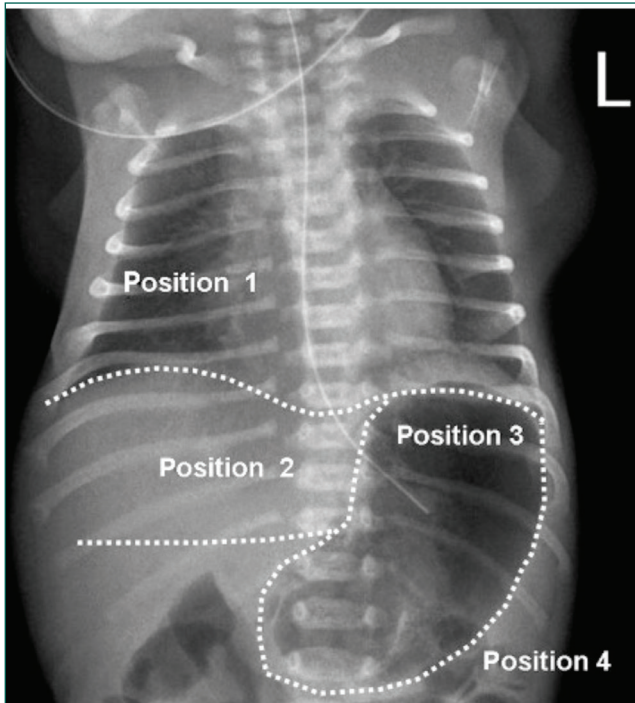
Two methods of radiographic analysis were used for the placement evaluation:

- Analysis by position,⁽¹⁰⁾ according to figure 1.

Position 5 was not used in the study because radiographs where tube visualization was difficult were excluded.

In the analysis by position, the gastric enteral tube was classified as high when corresponding to positions 1 and 2, in which the tube supposedly does not exceed the gastroesophageal sphincter.

Position 3 is considered correct, where the tube is in the gastric cavity. It is classified as low in position 4, where the tube touches the great curvature of the stomach or the tip is in the region of the pyloric sphincter.



Position 1- Tube above the diaphragm and gastroesophageal junction;
 Position 2- Tube under gastroesophageal junction and before the body of stomach;
 Position 3- Tube in the body of stomach (correct placement);
 Position 4- Tube touching greater curvature of the stomach or tip at pyloric sphincter region;
 Position 5- No classification on radiographs possible.

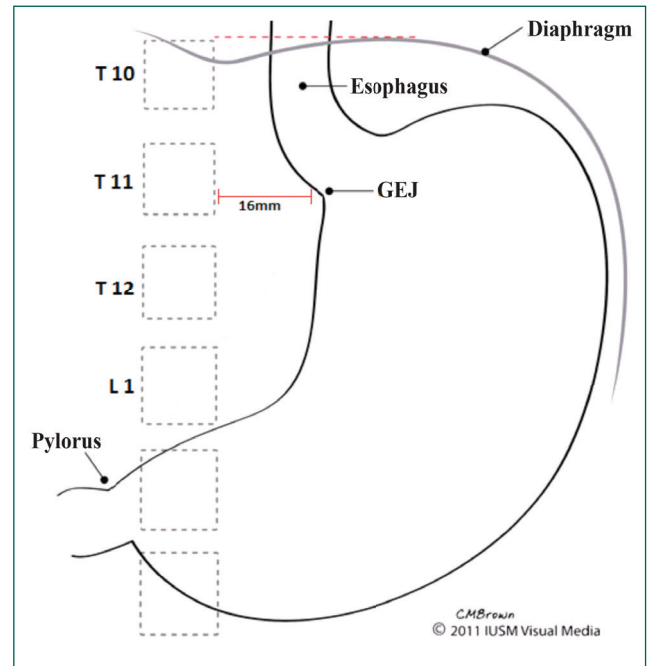
Source: Adapted from: Quandt D, Schraner T, Ulrich Bucher H, Arlettaz Mieth R. Malposition of feeding tubes in neonates: is it an issue? *J Pediatr Gastroenterol Nutr.* 2009; 48(5): 608-11.⁽¹⁰⁾

Figure 1. Positions of the tube in the thoracoabdominal radiography

- Analysis by vertebrae,⁽⁹⁾ according to gastroesophageal (GE) junction location by counting of vertebrae, as shown in figure 2.

It is believed there is a relatively fixed anatomical location of the GE junction, where the esophagus passes through the right side of the diaphragm. It was adopted that tubes below the 11th and 12th thoracic vertebrae and/or longer than 1.6 cm (16 mm) on the left side of the spine were located in the stomach.⁽⁹⁾

In the analysis by vertebrae, it was classified as high location when the tube tip was before the 10th thoracic vertebra, considered incorrect; and the correct location was between the 11th thoracic vertebrae and lumbar 1.



Source: Adapted from: Cohen MD, Ellett ML, Perkins SM, Lane KA. Accurate localization of the position of the tip of a naso/orogastric tube in children; where is the location of the gastroesophageal junction? *Pediatr Radiol.* 2011; 41(10):1266-71.⁽⁹⁾

Figure 2. Analysis by vertebrae

Professionals responsible for the analysis indicated individually the tube position in the data collection instrument according to the two aforementioned analyzes.

The study was approved by the Ethics and Research Committee under number 47063/2012, and complies with Resolution 466/12 of the National Health Council. It was authorized by the Research Coordination of the Nursing Board of the institution and the neonatal unit.

For data collection was used information of newborns' medical charts, and the analyzed radiographs had been previously performed for other diagnoses. Therefore, there was no direct contact or influence of researchers on patients' therapy. Since this is an observational study, the informed consent form for newborns' family members was not necessary.

Data analysis was performed in a Microsoft Office Excel file, and presented according to descriptive analysis, with absolute and relative values, considering an error of 0.05 and 95% confidence interval. To evaluate the concordance of evaluators, was used a Kappa concordance index, and values lower

than 20% were considered negligible agreement; from 21 to 40%, minimum; 41 to 60%, regular; 61 to 80%, good; and above 81% was optimal agreement. The chi-square test and ANOVA were used to analyze the association between variables and the enteral tube placement.

Results

Newborns whose radiographs were analyzed in this study were predominantly female (58.3%), with mean birth weight of 2112 grams (\pm 993), weight at the time of data collection of 2070 grams (\pm 989), and an average lifetime of 7.7 days (\pm 6.9). Apgar values and height are presented only in 52 newborns because there were out-of-hospital births and was not possible to obtain the Apgar value. The height was not measured due to minimal manipulation related to clinical severity of the newborn (Table 1).

The main medical diagnoses presented by newborns were prematurity associated with malformations and diseases (31.7%), followed by isolated malformations (26.7%). The most frequent malformations were congenital heart diseases (12.3%), followed by malformations of the central nervous system (9.1%). Among diseases, respiratory problems (14.3%) and congenital infection (13.6%) prevailed.

In relation to the therapy, the total number of drugs used by the 28 newborns was 104, mainly antibiotics (30.8%) followed by sedatives/analgesics (17.3%).

Regarding data on the respiratory support offered to newborns whose radiographs were analyzed in the study, most of them used some respiratory

support at the time of radiography, and mechanical ventilation (36.7%) was the most used type.

Most enteral tubes were used for drainage, and main gauges were numbers 6 and 8, inserted orally. In relation to the distance between the tube orifices, there was a great variation, which was related both to the different gauge of tubes and to the brand used in the unit at each moment. The number of orifices in the tubes ranged from one to four depending on the brand used.

The prevailing diets among preterm and term newborns were artificial formulas (61.9%) and less frequently breastmilk (38.1%), every 3 hours administered by bolus (71.4%).

The level of agreement among evaluators regarding the analysis of the enteral tube placement by position and by vertebrae was significant, classified as good (Kappa 78%) and optimum (Kappa 100%), respectively.

According to the criteria of analysis by position, most tubes were correctly placed according to evaluators 1 and 2, with the percentage ranged from 68.3 to 71.7%, respectively (Table 2).

According to the analysis by vertebrae proposed by Cohen,⁽⁹⁾ 57 (95%) tubes were after the gastroesophageal junction. Regarding the proper enteral tube placement, in only 45 tubes it was possible to measure the deviation to the left. According to primary data, 30 tubes (66.6%) had a deviation greater than or equal to 1.6 centimeters, with variation of \pm 1.02, therefore, located in the gastric cavity.

Among the 15 tubes in which it was not possible to measure the deviation to the left, eight were in the vertebral line, four were folded and three had the tip on the right side.

Table 1. Demographic characteristics of newborns with enteral tubes

Newborn's characteristics	n	Mean (Standard Deviation)	Median	Min	Max
Birth weight	60	2112 (\pm 993)	1735	740	4005
Weight at the moment of collection	60	2070 (\pm 989)	1770	720	4110
Gestational age (GA)	60	34 (\pm 4.8)	34	25	41
Corrected gestational age (CGA)	60	34.5 (\pm 4.5)	35	25	41
Days of life	60	7.7 (\pm 6.9)	5	1	28
Height	52	43.1 (\pm 4.8)	42.25	31	53
Apgar 1 st min	52	7.4 (\pm 1.7)	8.0	1	9
Apgar 5 th min	52	8.6 (\pm 1.5)	9.0	1	10

Table 2. Analysis by position according to evaluators 1 and 2

Analysis	Position	Evaluator 1 n(%)	Evaluator 2 n(%)
Correct	3	41(68.3)	43(71.7)
Incorrect		19(31.7)	17(28.3)
High	1	1(1.6)	1(1.6)
	2	4(6.6)	3(5.0)
Low	4	14(23.3)	13(21.7)
Total	-	60(100.0)	60(100.0)

By associating results of radiological evaluations by position and by vertebrae of tube placement in the gastric cavity, it was found that on average, 78% of the tubes measured by the modified NEX technique were adequately positioned.

In the association of variables with height, weight and gestational age of the newborn with the enteral tube placement, no statistically significant difference was found, considering the analysis by position of both evaluators (1 and 2). However, according to evaluator 2, the association with height was statistically significant ($p=0.05$).

In the analysis by vertebrae, although there was a mean difference between correct and incorrect placement of the enteral tube, for variables of gestational age ($p=0.92$), weight ($p=0.25$) and height ($p=0.12$) it was not considered statistically significant.

Discussion

In the analysis of the enteral tube placement according to radiological evaluation by position and vertebrae, on average in 78% there was correct placement in the gastric cavity, according to the modified NEX measurement. There was a statistically significant relationship of height with the tube placement only according to one evaluator when performing the analysis by position.

Enteral feeding is used when the newborn's gastrointestinal system is functioning, but the clinical condition or coordination of sucking, breathing and swallowing, that occurs near the 34th week of gestational age, is not established, and oral feeding is contraindicated. This is the case of the study sample, which is composed mainly of preterm infants (66.7%).

A study⁽⁴⁾ with newborns found a 47.5% rate of incorrect placement of gastric enteral tube when using the nose-ear-xiphoid (NEX) measurement.

Despite the knowledge about the error rate in enteral tube placement, studies do not indicate a relation between factors related to the adopted therapy and the cause of errors, like in the present study. Therefore, the relevant factor for the correct tube placement is the adopted measurement technique.

In the literature, no studies directly supporting the use of the NEX technique to estimate the enteral tube length have been found⁽¹¹⁾. Although the NEX technique has been used for years in pediatrics, this method has not been validated in the literature and studies have shown that tubes inserted with use of this technique are mostly misplaced, located above the gastroesophageal junction.⁽³⁾

The most recommended indication for measuring the enteral tube is the nose - ear - half the distance between the xiphoid appendix and the umbilicus (NEMU) technique,^(11,12-14) as it allows the tube location inside the body of the stomach. Such a recommendation is supported by the American Academy of Pediatrics Neonatal Resuscitation Program and the National Association of Neonatal Nurses.^(15,16)

In a randomized controlled trial⁽¹³⁾ performed with newborns, researchers used the following methods to measure the gastric tube length: in NB with height ≥ 44.5 cm, were used the NEX, NEMU and age-and-height formula. In the NB with height <44.5 cm, the NEX and NEMU techniques were selected. The result of this study demonstrated the tube placement in the gastric cavity in 91% of the sample when using the NEMU technique, 78% when using the formula, and 61% when using the NEX technique. All tubes used in the study had 1.5 cm of orifices.

In another study, the weight-based formula was used as auxiliary to the NEMU technique for enteral tube placement. However, the result was lower than expected, with incorrect placement in 16% of tubes, i.e., above or near the gastroesophageal junction. The authors suggested this result is justified by the fact that the nursing team did not fully incorporate the formula as a strategy to check the measure-

ment. When individually analyzing the 31 cases of incorrect placement, 22 (71%) of them could have been avoided if the formula had been used.⁽¹⁷⁾

Few studies report the measurement of the tip orifices of the tubes used, although this factor is important to ensure the administration of diet and medications in the gastric cavity. In studies where this value was reported, measurements ranged from 1.5 cm to 3.0 cm.^(9,13) However, in the neonatal unit investigated, values ranged between 0.6-3.8 cm, making it difficult to assert that all orifices are only inside the gastric cavity, given the wide range of the measurement that can affect the correct tube placement.

Researchers have developed a measurement formula for children younger than 28 months for nose/mouth enteral tubes: $1.95 + 0.372 \times (\text{height in cm})$. They state the NEX method should no longer be used to estimate the tube length, and recommended its substitution by the NEMU method or the formula considering age and height. However, the latter still requires further studies for preterm newborns.⁽¹³⁾

In another study, the correct location of the enteral tube length estimated according to weight was verified by radiograph. The NEX measurement method was used by starting on the tip of the nose if nose enteral tube, or the corner of the mouth if a mouth enteral tube, and adding one centimeter for children weighing less than or equal to 1000g; and two centimeters for children weighing more than 1000g. A total of 218 radiographs were analyzed. They corresponded to 87 newborns weighing 397 to 4131g, and gestational age of 23 to 42 weeks. It was found that 74% of the tubes were correctly positioned.⁽¹⁸⁾

The assertiveness index using the NEX method (modified technique used in this study) by disregarding the tube orifices ranged from 68.3% to 71.7% according to analysis by position and 95% in the analysis by vertebrae. The error found resembles that described in the literature, with rates ranging from 5.0% to 31.7% of tubes in malposition, according to the analysis by vertebrae and positions, respectively.

Although the indexes of placement error are similar to those found in the literature, these values are

high and can compromise newborn's safety, especially when considering the high number of tubes with post-pyloric placement.

The modified NEX technique can be compared to the NEMU. However, given the great variation between proximal and distal orifices of enteral tubes in the different brands and gauges, even considering a small variation of the tube gauges (with a predominance of 6 and 8 Fr), the use of the modified NEX technique should be discouraged in clinical practice in newborns because it implies the risk of incorrect placement in the gastric cavity.

Although the radiography is considered gold standard for determining the gastric tube placement, in 20% of cases its position cannot be indicated with certainty related to the difficult visualization. From this fact, a study was conducted with preterm and full term newborns in order to evaluate if the injection of air in newborns' stomach seconds before the radiography improved the radiological evaluation. Five ml of air were injected into preterm NB and 10 ml into term NB about 5 seconds before the radiography. The group in which air was injected showed the exact location of 95% of tubes, while in the control group the rate was 78%. The conclusion is the injection of air in the gastric cavity before the radiography significantly improves the evaluation of the exact tube placement.⁽¹⁹⁾

The limitations of the study are the wide variation of characteristics of the tubes that may have influenced the control of the variable, in addition to the partial absence of data regarding height.

One of the contributions of the study was the finding that the use of the modified NEX technique should be discontinued in neonatal units, given the present study results and the absence of any scientific evidence to support it, mainly because of the lack of standardization of the distance of enteral tube orifices.

Thus, the NEMU technique is still the best indication in the neonatal context, although it does not present correct placement in all cases, because of variations in newborns' biometric characteristics. This demonstrates the need for further stud-

ies, especially in premature infants by adopting NEMU measurements or the formula and considering these characteristics.

Conclusion

Correct enteral tube placement according to the modified NEX technique that disregards the orifices at the distal end of the tube, was identified, according two evaluators from 68.3% to 71.7% using the position analysis, and 95 % using the vertebrae analysis. The modified technique presented values similar to those described in the literature, with correct placement in most newborns, but with an error index of 31.7% in analysis by position and 5.0% in analysis by vertebrae, which allows concluding this technique should not be encouraged.

Collaborations

André RR, Mendes CQS, Balieiro MMFG and Avelar AFM collaborated in the stages of study design, analysis, data interpretation, article writing, critical review of the intellectual content and final approval of the version to be published.

References

- Gregory KE, Connolly TC. Enteral Feeding Practices in the NICU: Results from a 2009 Neonatal Enteral Feeding Survey. *Adv Neonatal Care*. 2012; 12(1):46-55.
- Wallace T, Steward D. Gastric tube use and care in the NICU. *NAINR*. 2014; 14: 103-108.
- Dias FS, Emidio SC, Lopes MH, Shimo AK, Beck AR, Carmona EV. Procedures for measuring and verifying gastric tube placement in newborns: an integrative review. *Rev Lat Am Enfermagem*. 2017;25: e2908.
- Boer JC, Smit BJ, Mainous RO. Nasogastric tube position and intragastric air collection in a neonatal intensive care population. *Adv Neonatal Care*. 2009; 9(6): 293-8.
- Nyqvist KH, Sorell A, Ewald U. Litmus tests for verification of feeding tube location in infants: evaluation of their clinical use. *J Clin Nurs*. 2005;14(4):486-95.
- Metheny NA, Meert KL. A review of published case reports of inadvertent pulmonary placement of nasogastric tubes in children. *J Pediatr Nurs*. 2014; 29(1): e7-e12.
- Ellett ML. What is known about methods of correctly placing gastric tubes in adults and children. *Gastroenterol Nurs*. 2004; 27(6): 253-9; quiz 260-1.
- Irving SY, Lyman B, Northington L, Bartlett JA, Kemper C; Novel Project Work Group. Nasogastric tube placement and verification in children: review of the current literature. *Crit Care Nurse*. 2014; 34(3): 67-78.
- Cohen MD, Ellett ML, Perkins SM, Lane KA. Accurate localization of the position of the tip of a naso/orogastric tube in children; where is the location of the gastro-esophageal junction? *Pediatr Radiol*. 2011; 41(10):1266-71.
- Quandt D, Schraner T, Ulrich Bucher H, Arlettaz Mieth R. Malposition of feeding tubes in neonates: is it an issue? *J Pediatr Gastroenterol Nutr*. 2009; 48(5): 608-11.
- Ellett MLC, Cohen MD, Perkins SM, Smith CE, Lane KA, Austin JK. Predicting the insertion length for gastric tube placement in neonates. *J Obstet Gynecol Neonatal Nurs*. 2011; 40(4):412-21.
- Clifford P, Heimall L, Brittingham L, Davis KF. Following the evidence: Enteral tube placement and verification in neonates and young children. *J Perinat Neonatal Nurs*. 2015; 29(2):149-61.
- Beckstrand J, Ellett ML, McDaniel A. Predicting internal distance to the stomach for positioning nasogastric and orogastric feeding tubes in children. *J Adv Nurs*. 2007; 59(3):274-89.
- National Guideline Clearinghouse. Best evidence statement (BEST). Confirmation of nasogastric/orogastric tube (NGT/OGT) placement. 2011 [cited 2017 Jan 12]. Available from: <https://www.guideline.gov/summaries/summary/35117/best-evidence-statement-best-confirmation-of-nasogastricorogastric-tube-ngtogg-placement>.
- Kattwinkel J, Bloom RS. American Academy of Pediatrics, American Heart Association. *Neonatal Resuscitation Textbook*. 6th ed. Dallas, TX: American Academy of Pediatrics; 2011.
- Ikuta LM, Beauman SS. Policies, Procedures and Competences for Neonatal Nursing. Glenview, IL: National Association of Neonatal Nurses; 2011.
- Nguyen S, Fang A, Saxton V, Holberton J. Accuracy of a weight-based formula for neonatal gastric tube insertion length. *Adv Neonatal Care*. 2016; 16(2):158-61.
- Freeman D, Saxton V, Holberton J. A Weight-Based Formula for Estimating Gastric Tube Insertion Length in Newborns. *Adv Neonatal Care*. 2012; 12(3):179-82.
- Quandt D, Brons E, Schiffer PM, Schraner T, Bucher HU, Mieth RA. Improved radiological assessment of neonatal feeding tubes. *Arch Dis Child Fetal Neonatal Ed*. 2013; 98(1):F78-80.