

# Subacute cognitive impairment, hyponatremia and mesial temporal lobe lesions

A typical presentation of voltage-gated potassium channel (VGKC) antibody-associated limbic encephalitis

Thais Saccardi, José Luiz Pedroso, Tenille Bernardino,  
Orlando G.P. Barsottini, Henrique Ballalai Ferraz

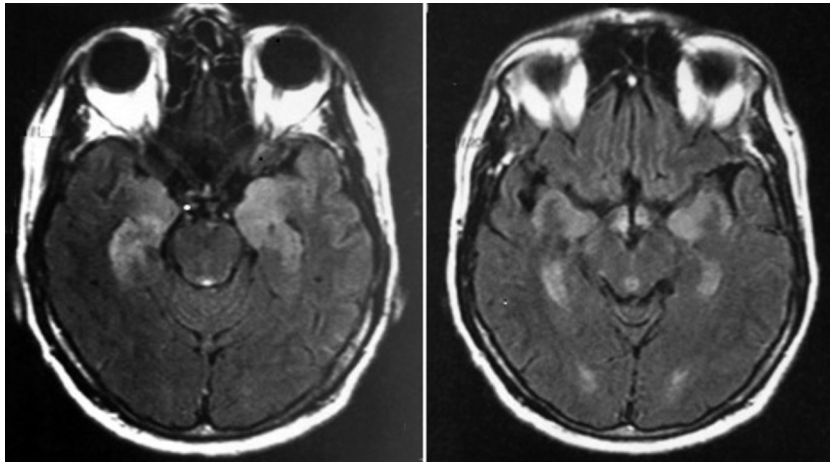
For many years, several reports have called attention for non-viral limbic encephalitis (LE), particularly with paraneoplastic etiology. However, an increasing number of data have demonstrated that some of those disorders are immune-mediated with antibodies to voltage-gated potassium channels (VGKC)<sup>1</sup>.

Herein, we present a case of VGKC antibody-associated LE and discuss the main phenotypic and imaging features of this unusual disease.

## CASE

A 50-year-old man presented to our hospital with three months history of progressive personality change, sleep disturbance, memory impairment, visual hallucinations and seizures. Neurological examination showed

disorientation, cognitive impairment (Mini Mental State Examination: 13) and memory dysfunction. Blood tests showed hyponatremia - 130 mmol/L (135-145 mmol/L). Thyroid function, antibodies and serologic tests were normal. Cerebrospinal fluid showed high level of proteins (558 mg/dL) and mild lymphocytic pleocytosis. Brain magnetic resonance imaging (MRI) disclosed bilateral T2 and FLAIR hyperintensity of mesial temporal lobes (Figure). Cancer investigation resulted negative. VGKC serum level was higher than 650 pmol/L (normal range less than 450 pmol/L). These findings confirmed the diagnosis LE with VGKC antibodies. Methylprednisolone was started, with partial improvement. Three weeks later, immunoglobulin 0.4 g/Kg daily for five consecutive days was initiated. One week after immunoglob-



**Figure.** Axial FLAIR sequence brain MRI disclosed bilateral mesial temporal hyperintensity.

ulin therapy, the patient presented a clear improvement and achieved a MMSE score of 26.

### DISCUSSION

Recent data have described LE caused by antibodies to VGKC, a specific cell-membrane antigen<sup>1,2</sup>. Other antibodies related to LE include NMDA, AMPAR and GABA<sup>3,4</sup>. Although LE is frequently related to auto-immune etiology, a paraneoplastic syndrome is found in 30% of the cases<sup>3</sup>. When hyperhidrosis, autonomic dysfunction, psychiatric symptoms and neuromyotonic discharges are present, Morvan syndrome must be suspected<sup>5</sup>.

Although often unrecognized, the neurological spectrum of VGKC antibody-associated LE includes seizures and neuropsychiatric symptoms, ranging from alterations in memory, behavior, and cognition<sup>1</sup>. Neuroimaging shows bilateral hyperintense sign in mesial temporal lobe<sup>1</sup>. Imaging differential diagnosis includes: herpetic and paraneoplastic encephalitis, status epilepticus, other immunomediated encephalitis (e.g., anti-NMDA, anti-VGKC) and Alzheimer disease due to the S170F mutation in the presenilin 1 (PS-1) gene<sup>2</sup>. Hyponatremia occurred in 60% of patients and might be attributed to the expression of leucine-rich, glioma-inactivated 1 (LGI1) in the hypothalamus<sup>2</sup>.

Recently, Lai et al. described that LGI1 is the autoantigen associated with LE previously attributed to VGKC antibodies. Several patients with the typical syndrome presented

negative VGKC and positive LGI1 antibodies<sup>2</sup>. The majority of the patients favorably respond to immunotherapy. Administration of human immunoglobulin or plasma exchange is the first line treatment. Methylprednisolone can also be effective. Several patients required chronic therapy on lower dose steroids, with or without azathioprine<sup>5</sup>.

### REFERENCES

1. Bataller L, Kleopa KA, Wu GF, Rossi JE, Rosenfeld MR, Dalmau J. Autoimmune limbic encephalitis in 39 patients: immunophenotypes and outcomes. *J Neurol Neurosurg Psychiatry* 2007;78:381-385.
2. Lai M, Huijbers MGM, Lancaster E, et al. Investigation of LGI1 as the antigen in limbic encephalitis previously attributed to potassium channels: a case series. *Lancet Neurol* 2010;9:776-785.
3. Graus F, Saiz A, Lai M, et al. Neuronal surface antigen antibodies in limbic encephalitis: clinical: immunologic associations. *Neurology* 2008;16: 930-936.
4. Shimazaki H, Ando Y, Nakano I, Dalmau J. Reversible limbic encephalitis with antibodies against the membranes of neurones of the hippocampus. *J Neurol Neurosurg Psychiatry* 2007;78:324-325.
5. Merchut MP. Management of voltage-gated potassium channel antibody disorders. *Neurol Clin* 2010;28:941-959.

### DECLÍNIO COGNITIVO SUBAGUDO, HIPONATREMIA E LESÕES TEMPORAIS MESAIS: UMA APRESENTAÇÃO TÍPICA DE ENCEFALITE LÍMBICA ASSOCIADA A ANTICORPOS CONTRA CANAIS DE POTÁSSIO VOLTAGEM DEPENDENTES (VGKC)

Department of Neurology and Neurosurgery, Universidade Federal de São Paulo, São Paulo SP, Brazil.

**Correspondence:** Thais Saccardi - Rua Botucatu 740 - 04023-900 São Paulo SP - Brasil. E-mail: thaissaccardi@yahoo.com.br

Received 15 May 2011. Received in final form 19 July 2011. Accepted 26 July 2011.